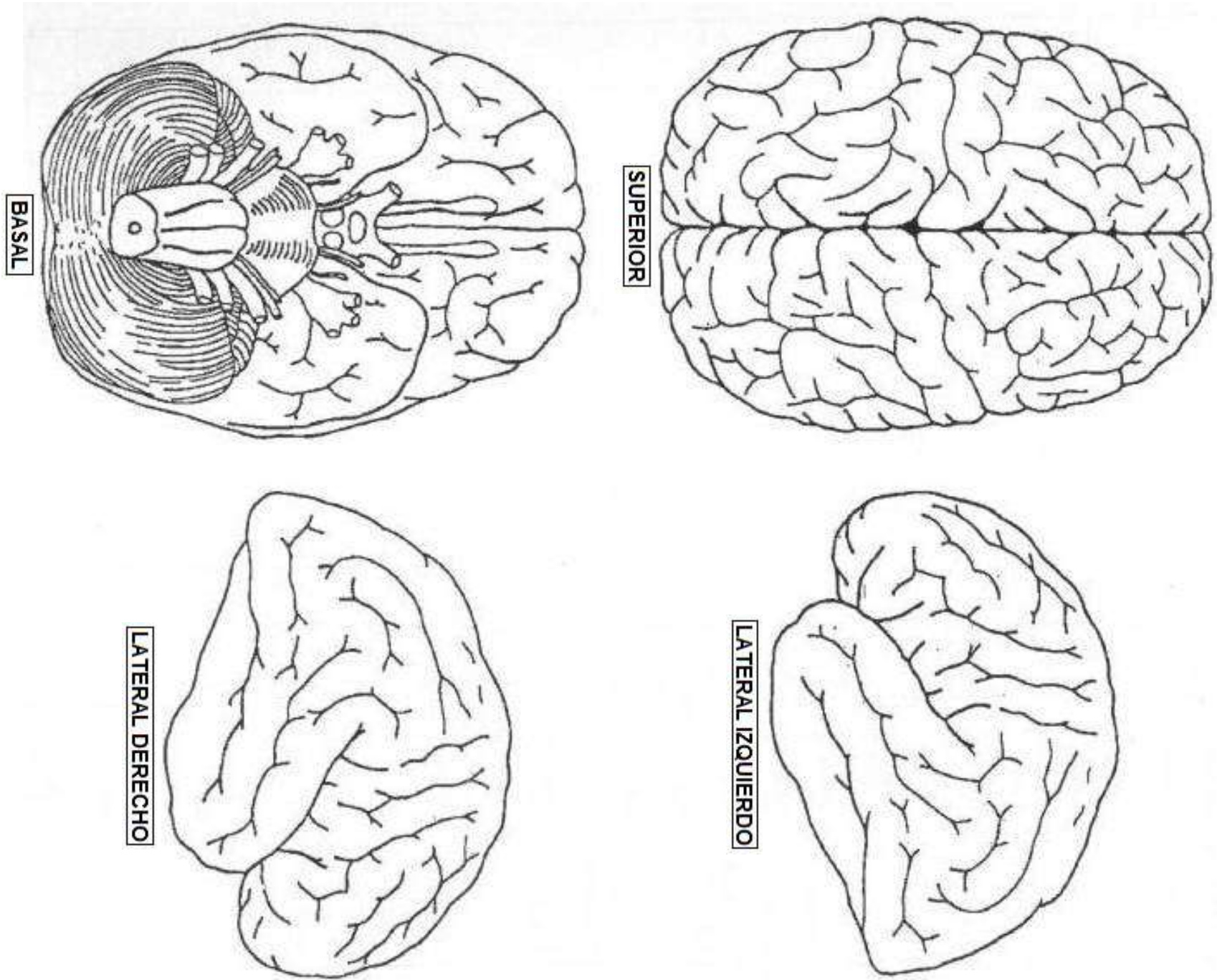
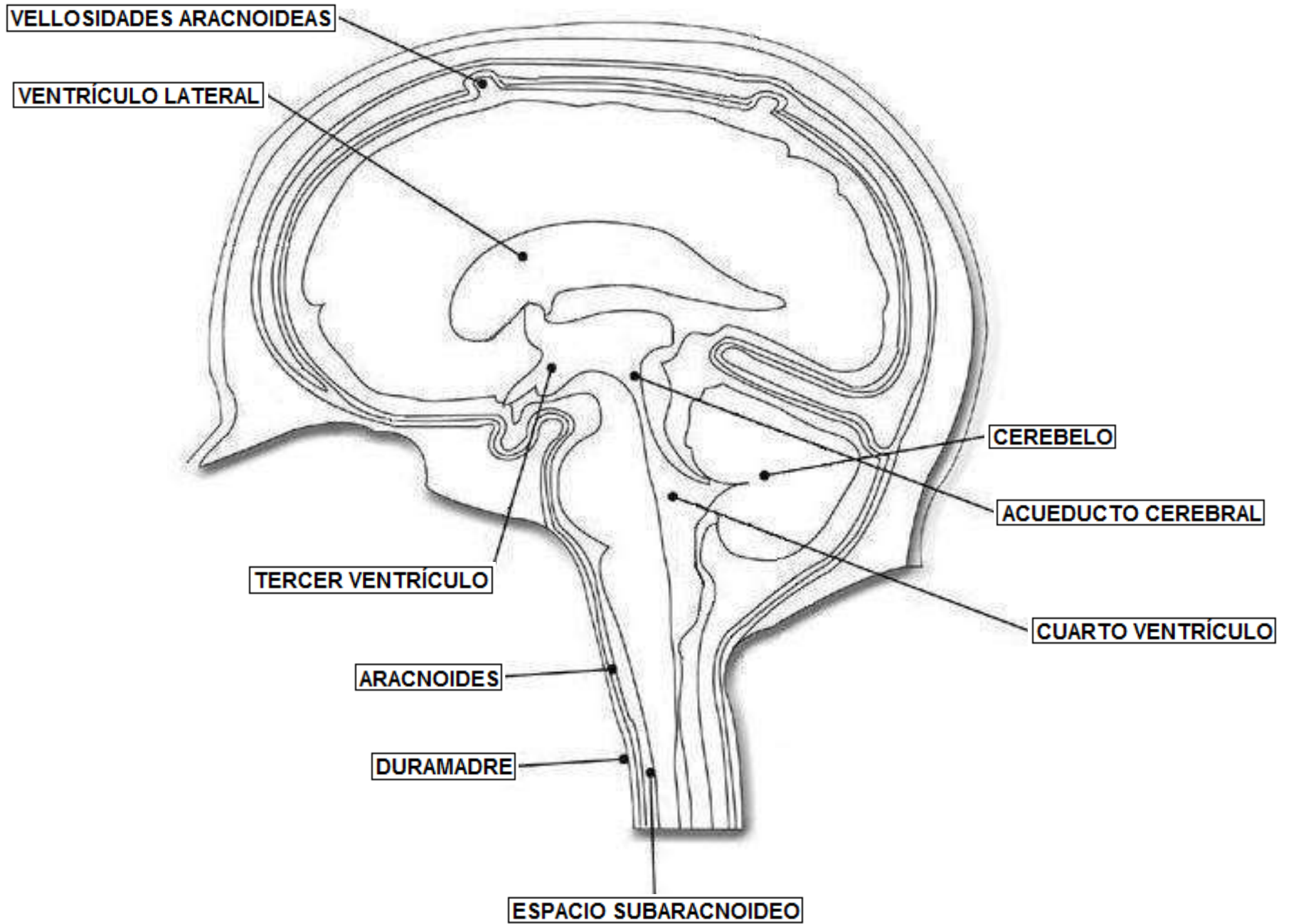


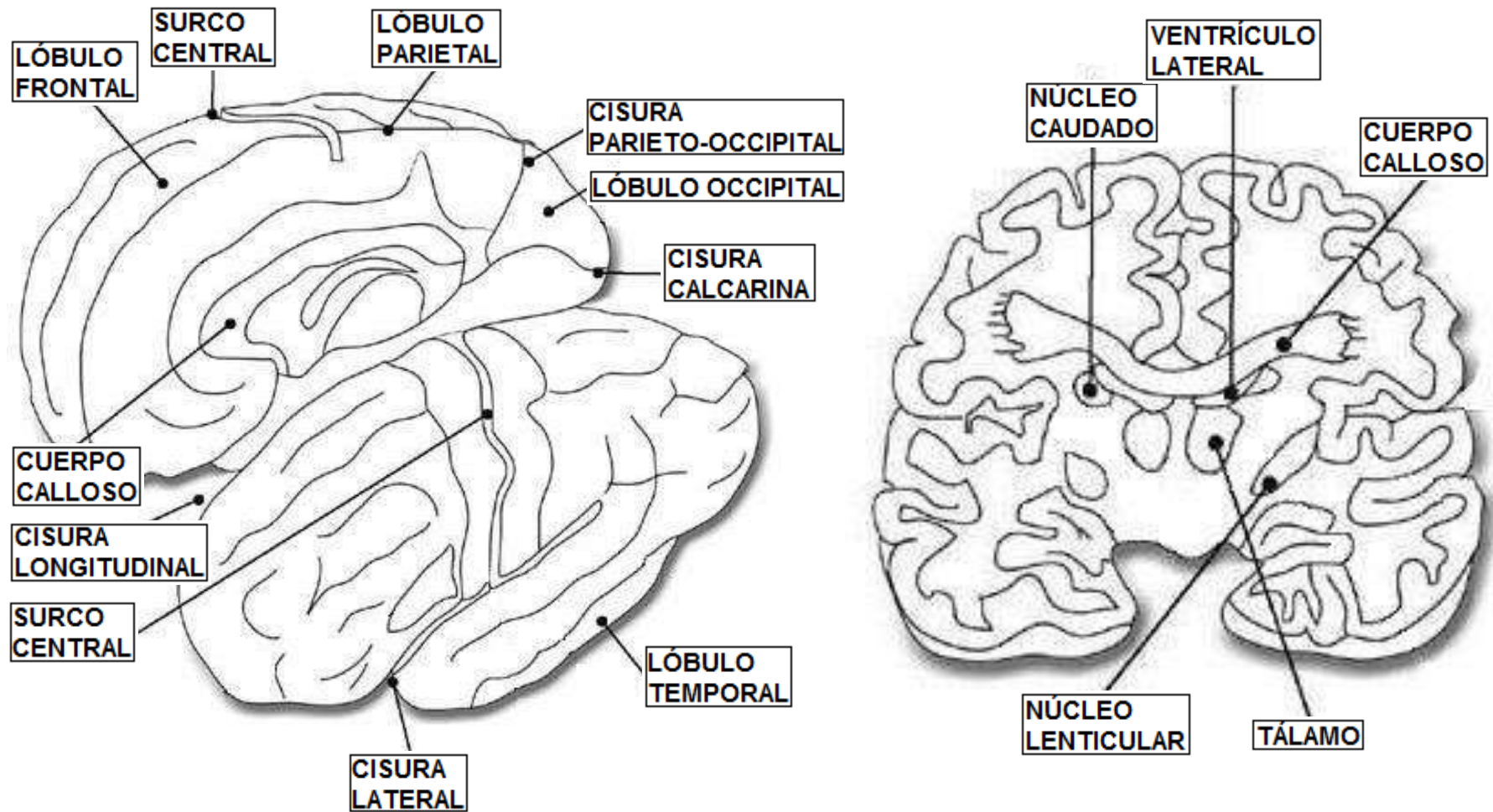
**Figura No. 1.** Encéfalo. Vista superior, basal, lateral izquierda y derecha.



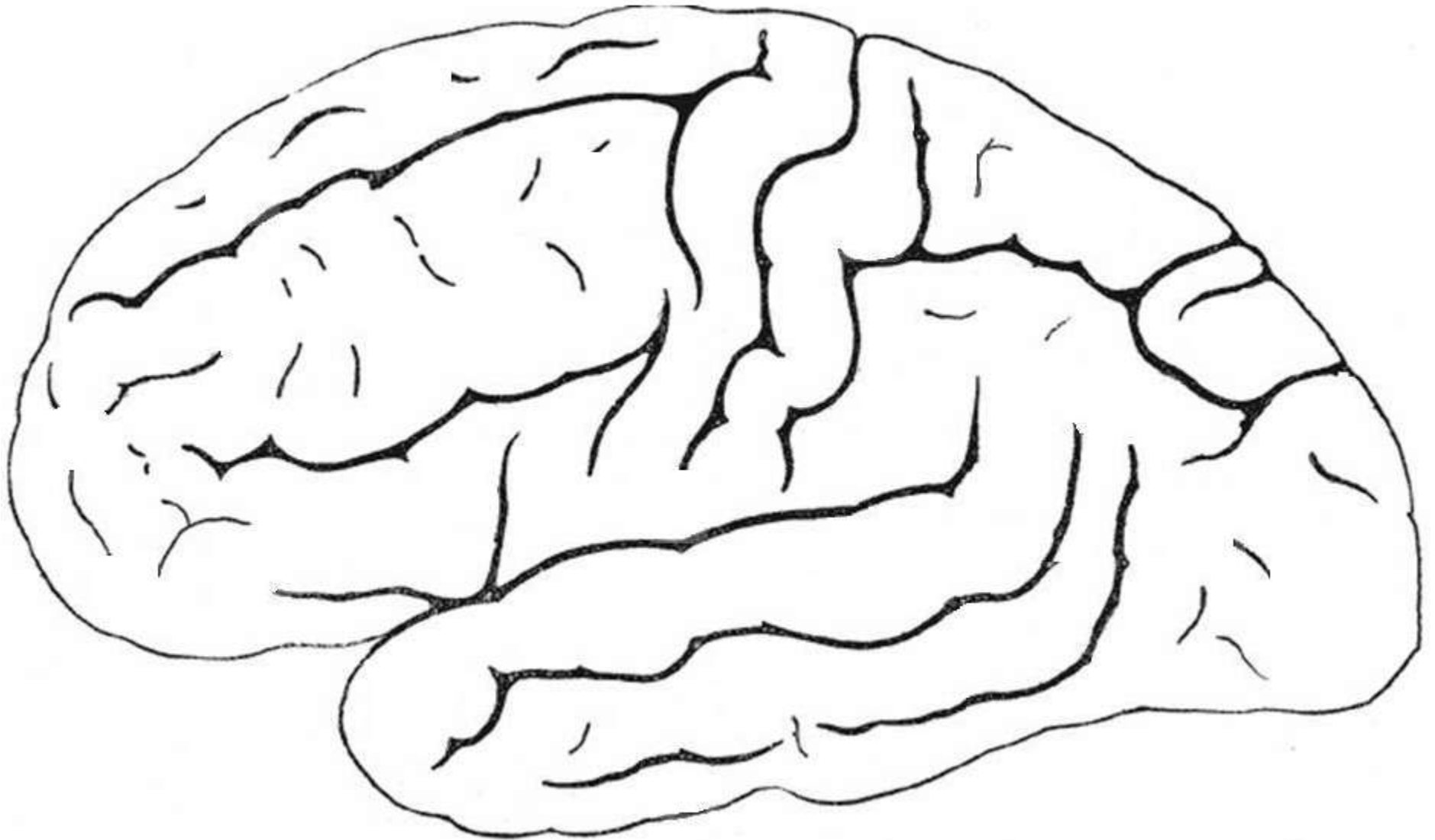
**Figura No. 2.** Encéfalo. Plano sagital.



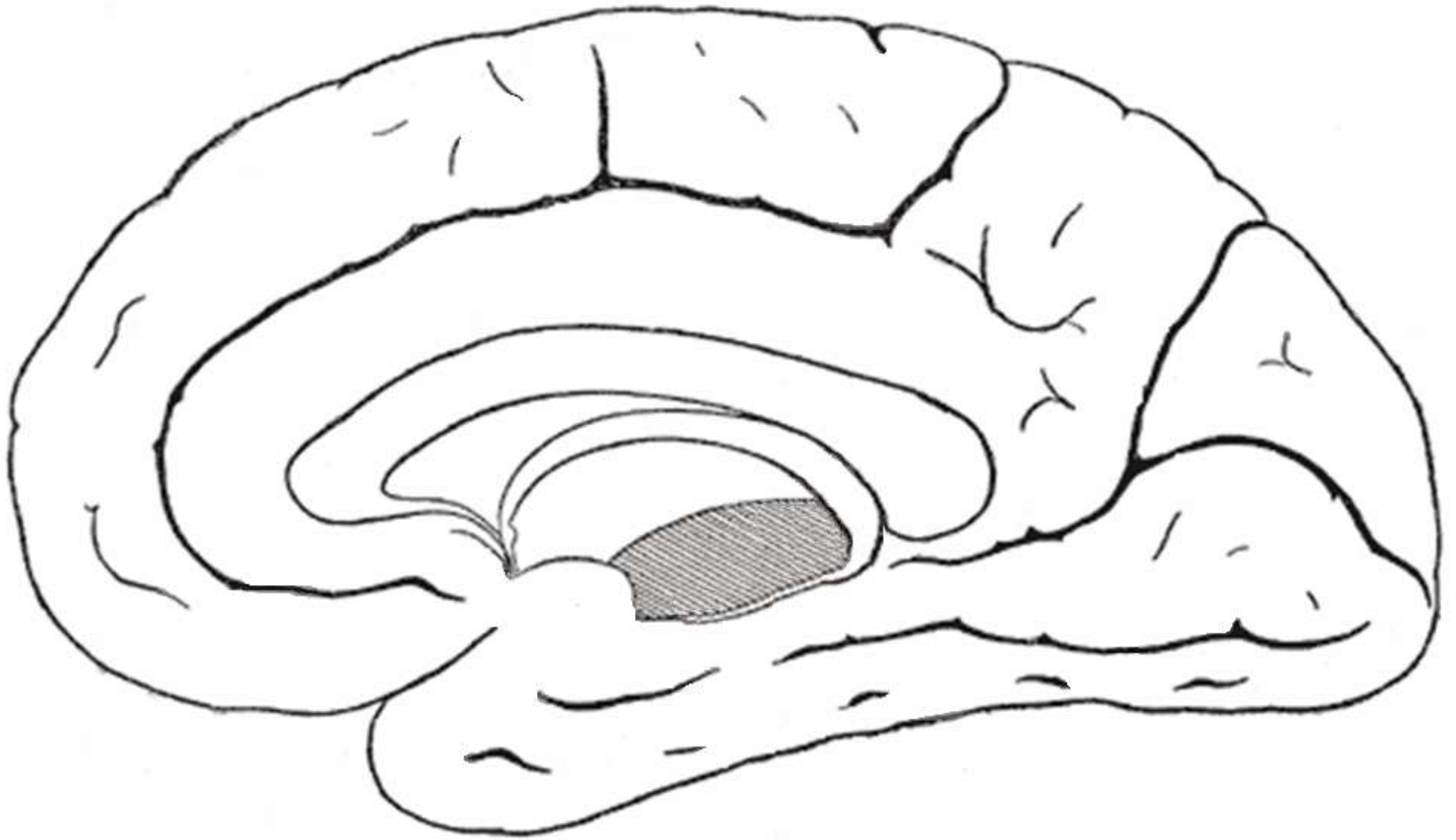
**Figura No. 3.** Cerebro. Plano coronal.



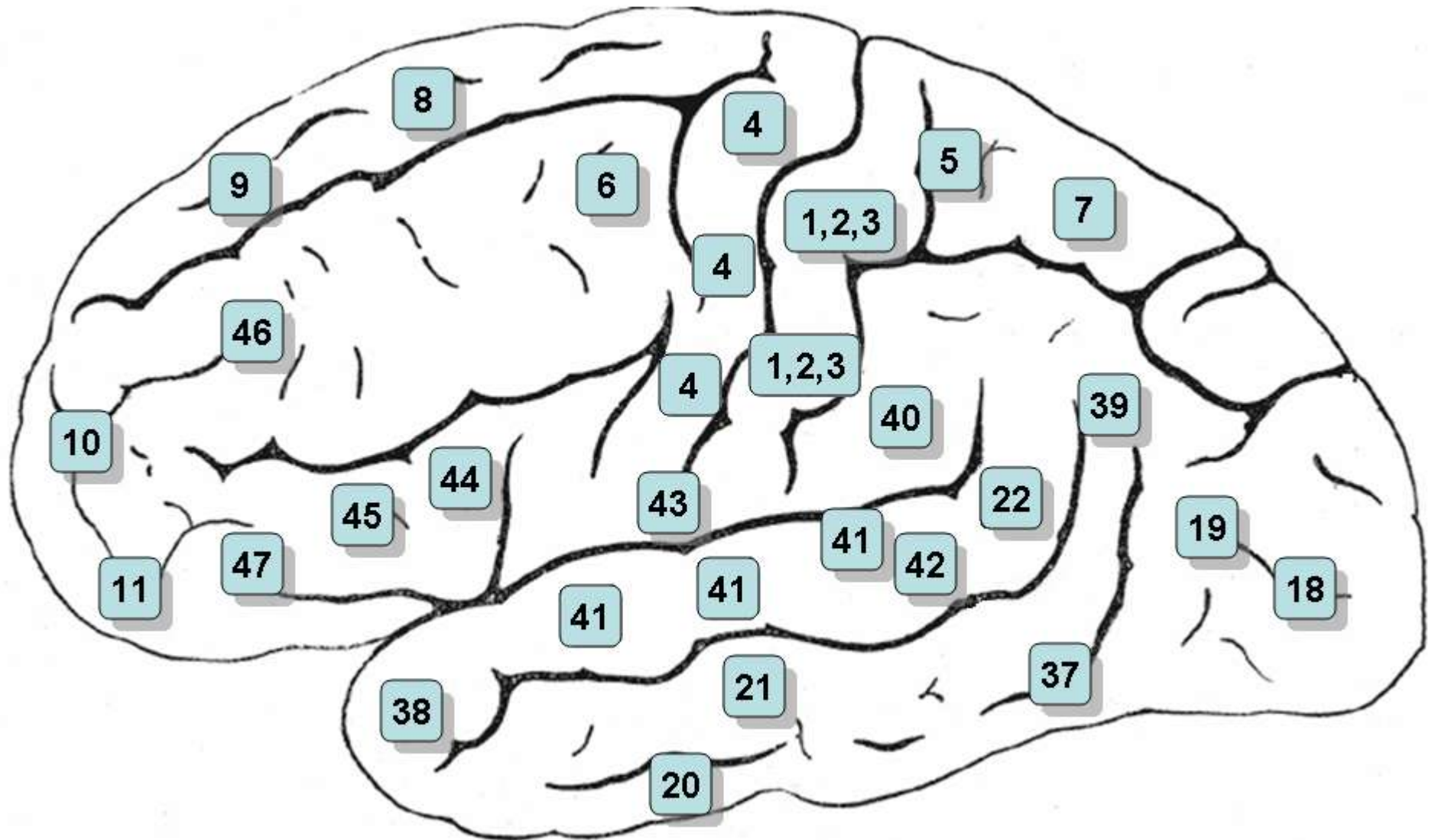
**Figura No. 4.** Hemisferio cerebral izquierdo. Vista lateral.



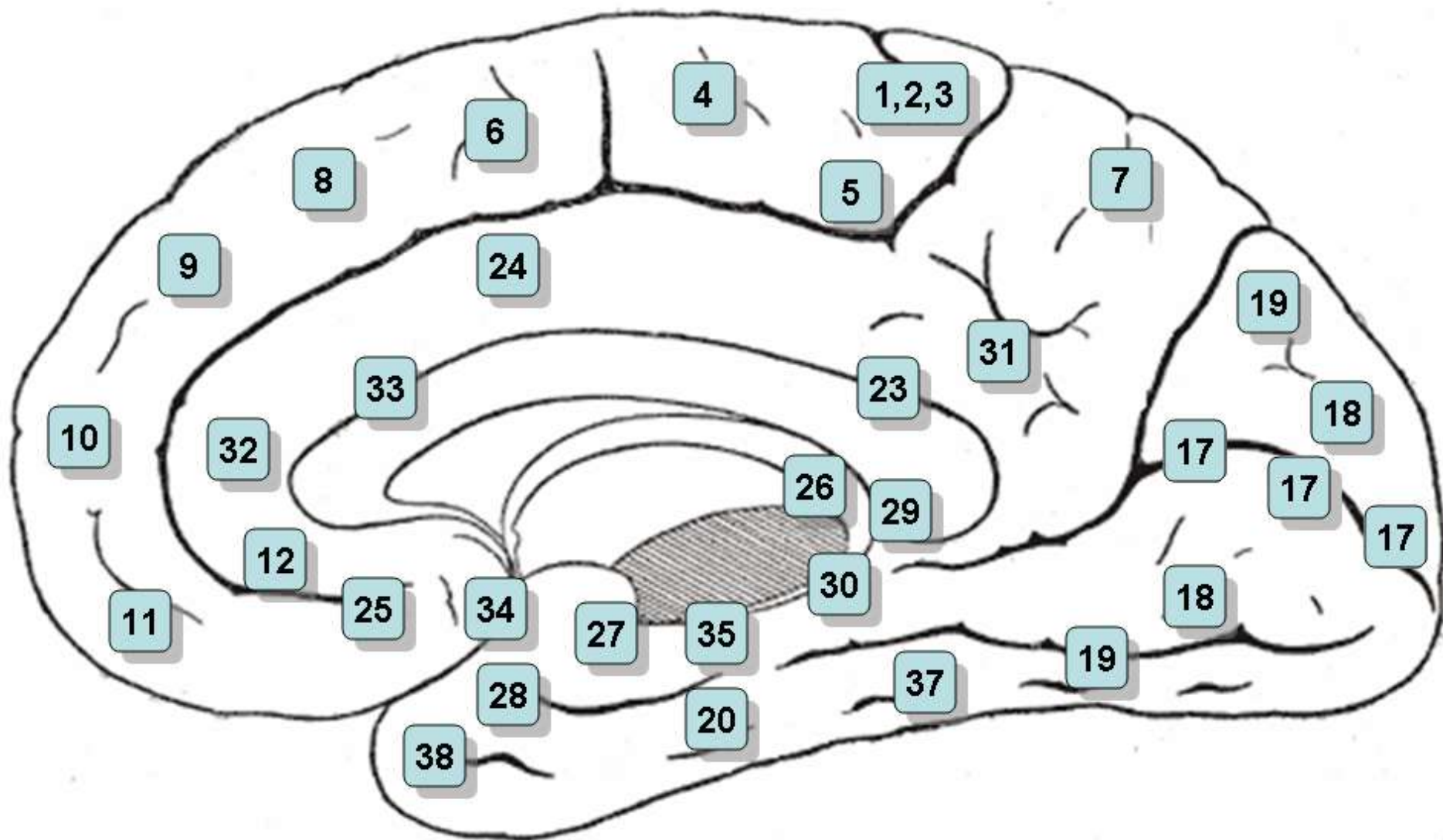
**Figura No. 5.** Hemisferio cerebral derecho. Vista media.



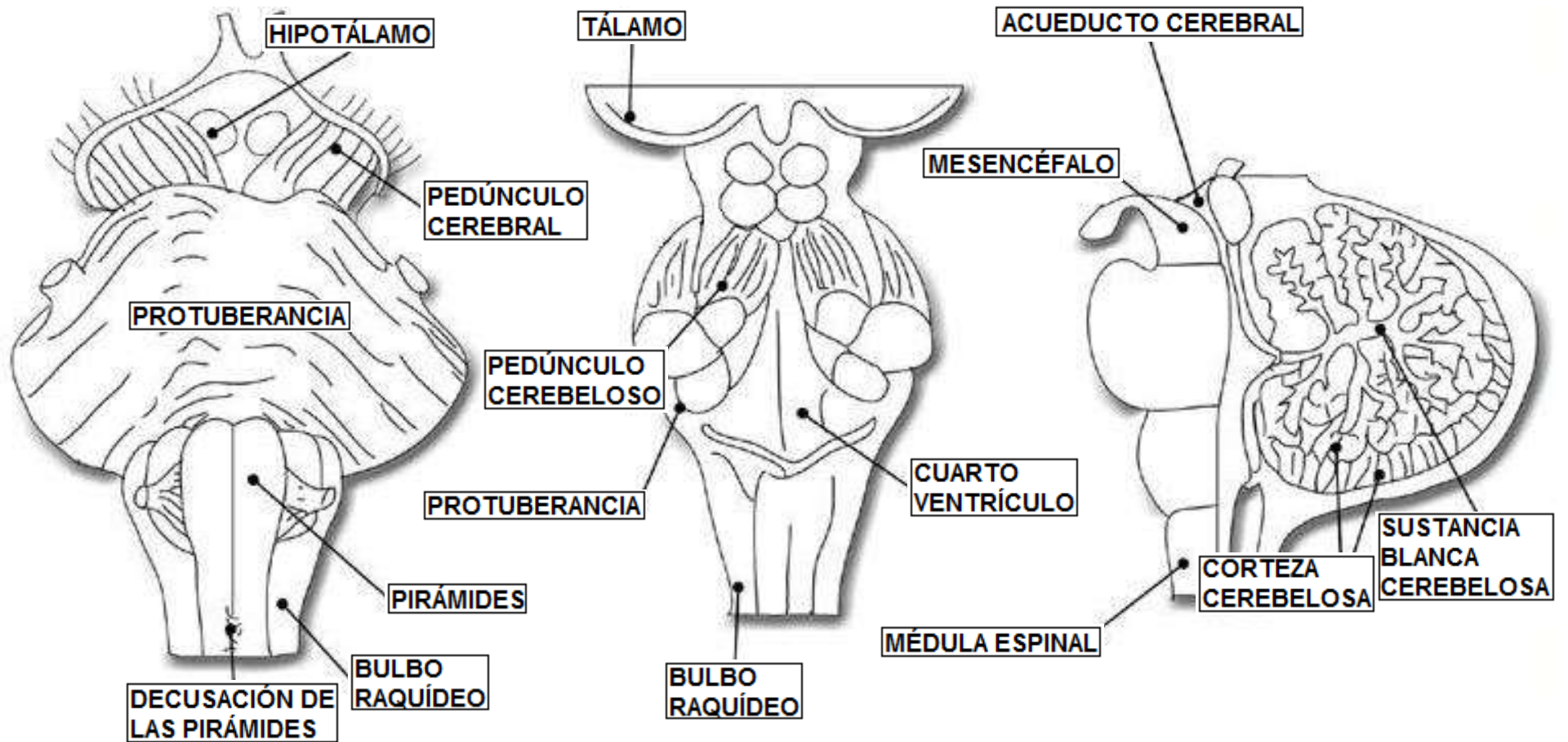
**Figura No. 6.** Corteza cerebral. Vista lateral.



**Figura No. 7.** Corteza cerebral. Vista media.

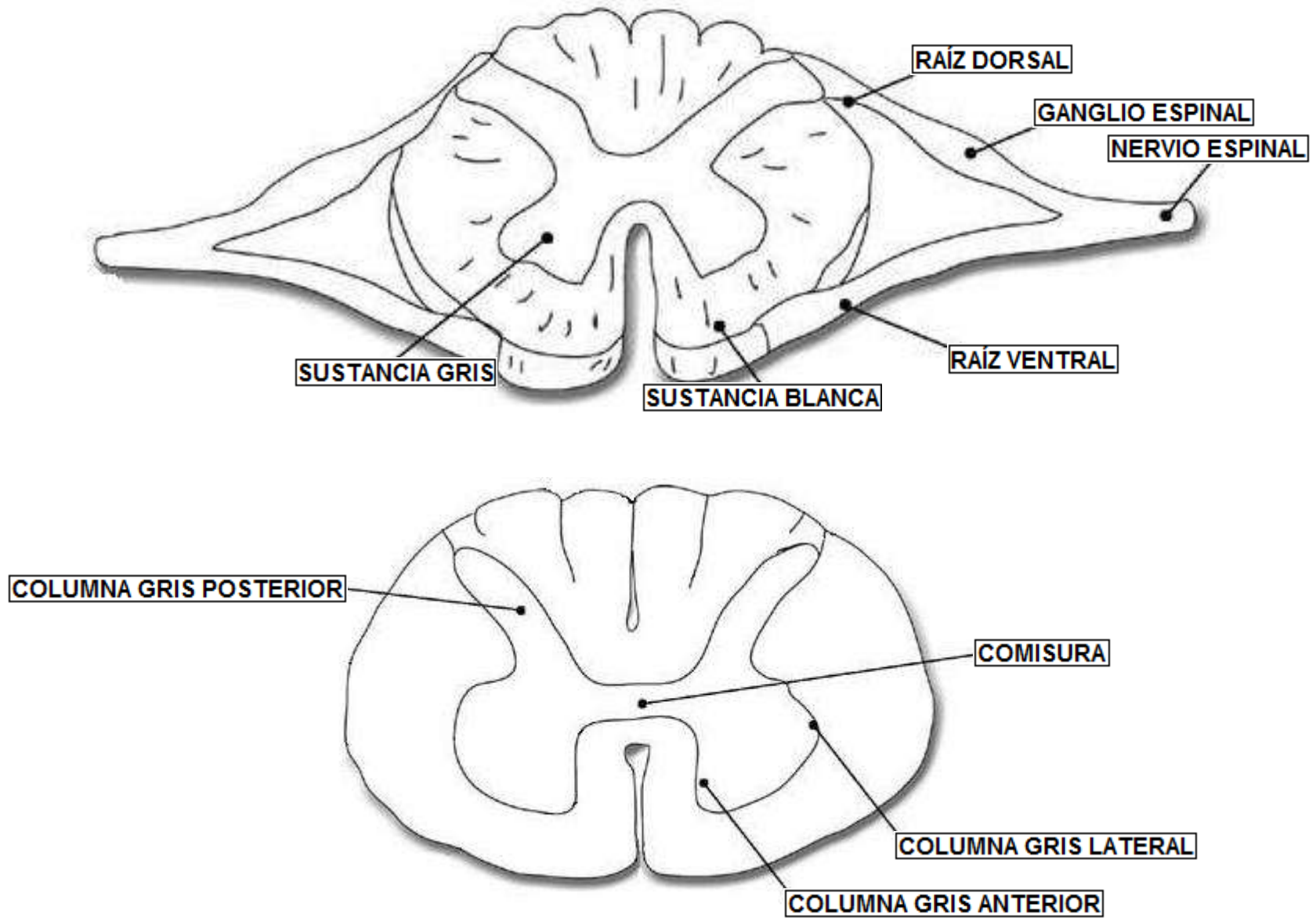


**Figura No. 8.** Tronco encefálico. Vista ventral, dorsal y plano sagital.





**Figura No. 9.** Médula espinal. Segmento y plano transversal.



**Figura No. 10.** Sistemas motor somático y sensorial somático.

